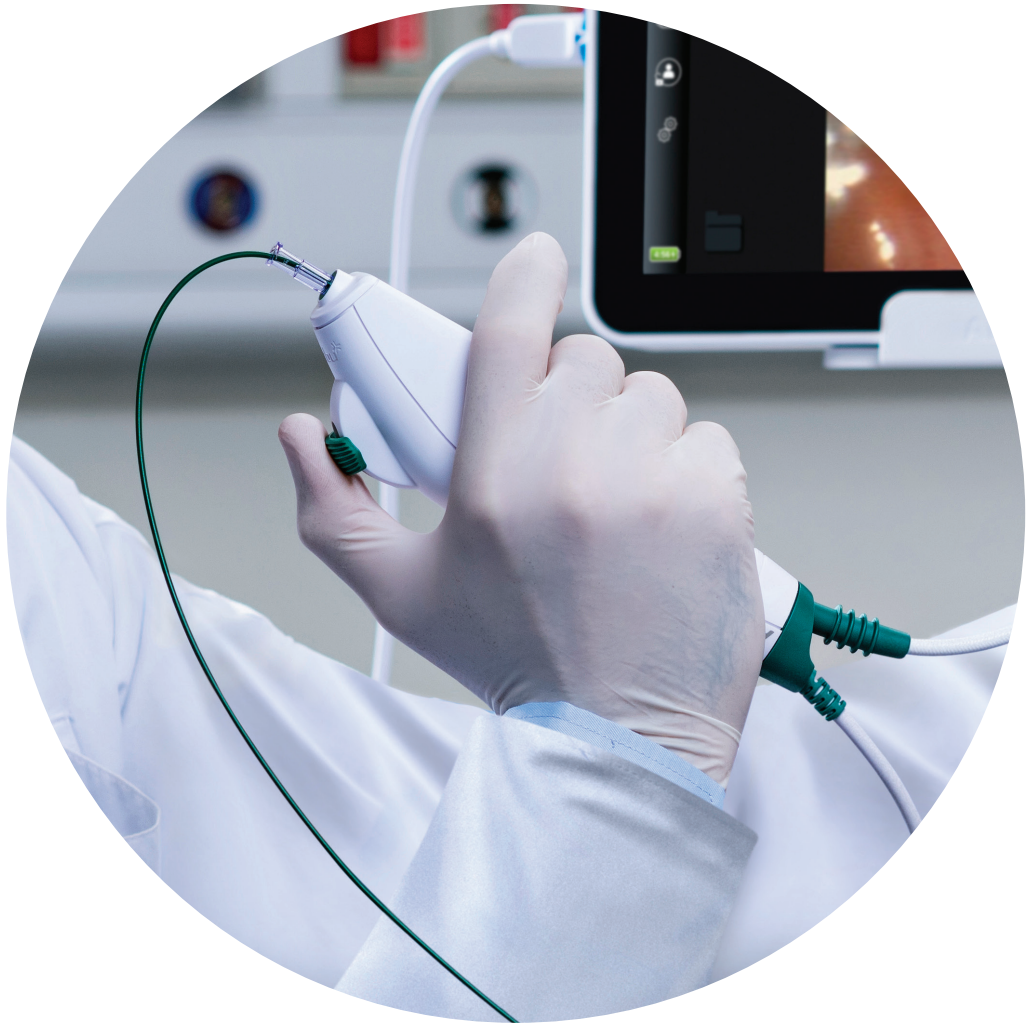

IN THE OUTPATIENT SETTING

Ambu® aScope™ 4 RhinoLaryngo Intervention



Ambu

The gold standard for obtaining diagnostic tissues for lesions of the larynx, oropharynx, and hypopharynx has been under general anaesthesia in the operating theatre. This procedure has higher demands for resources, e.g., scheduling theatre time, requiring overnight or day-case hospital bed, and carries the risk of general anaesthesia unfit for some patients. During the COVID-19 pandemic, access to the operating theatre has been significantly reduced, which has prolonged diagnostic waiting times, compromising early diagnosis and treatment.¹

The advent of flexible scopes with a biopsy channel has technically enabled the clinicians to perform in-office biopsies with local anaesthetic during the initial investigation.

Publications on in-office upper airway biopsy have concurred that this procedure is safe, feasible, cost-effective, and easy to perform.²⁻⁶ Most importantly, an in-office biopsy can often be performed during the initial outpatient visit or follow-up visit, which results in reduced diagnostic delay.⁷

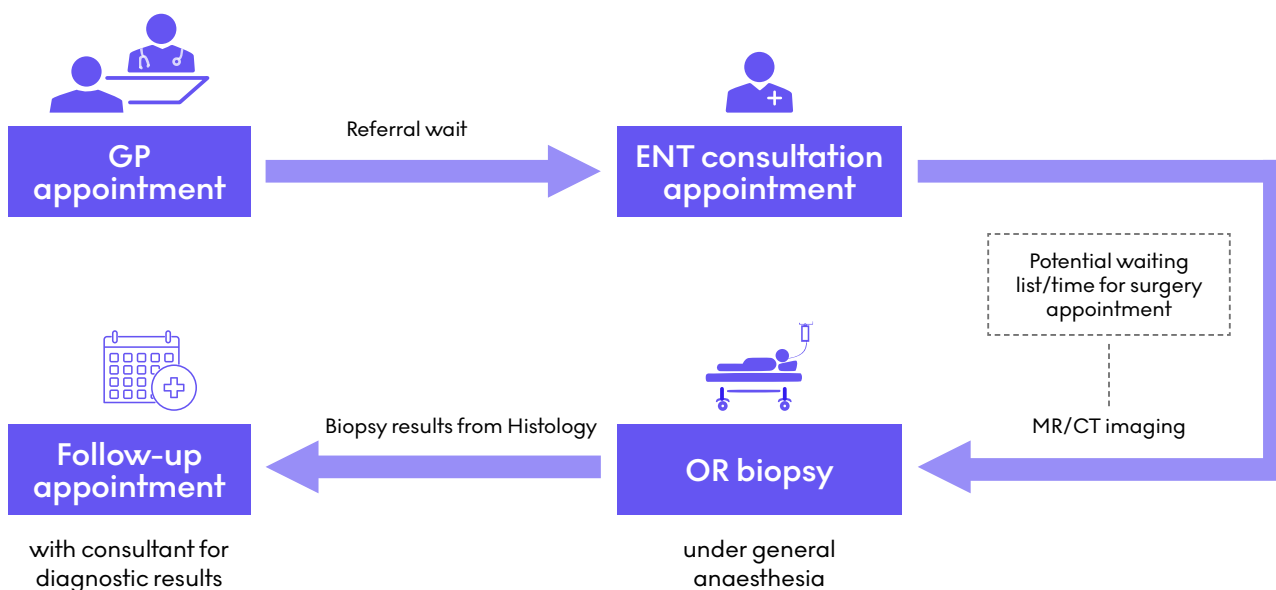
The Ambu® aScope™ 4 RhinoLaryngo Intervention comes with a 2.2 mm working channel for the insertion of biopsy forceps and other endoscopic accessories and is a good choice for therapeutic procedures. It is ready when you are, requires no post-procedural handling and comes at a low investment cost, which makes it particularly suitable for outpatient-clinic biopsies.

IN-OFFICE BIOPSY AS A COMPLEMENTARY METHOD

Moving ENT biopsy procedures from theatre to the outpatient setting

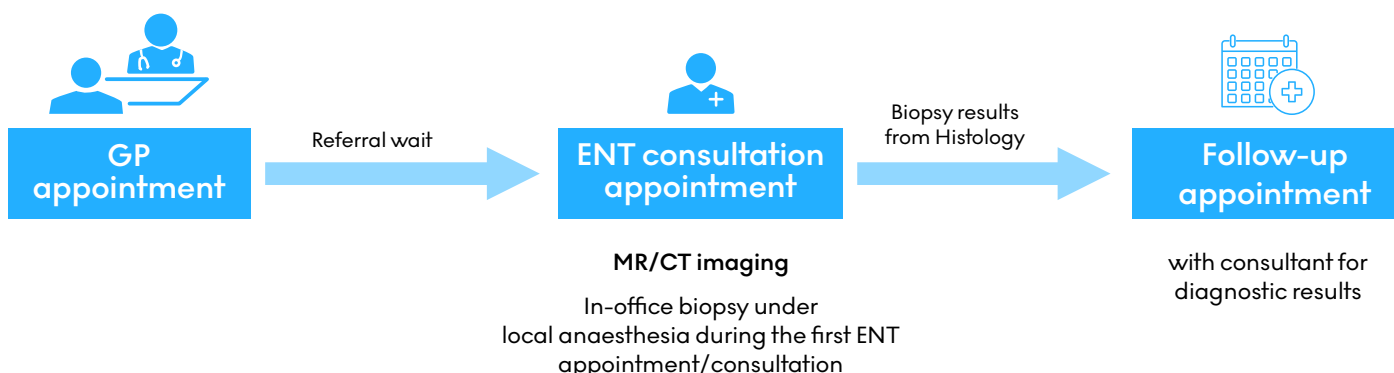
Current standard of care pathway

Operating theatre biopsy



Optimised patient pathway

In-office biopsy using flexible rhinolaryngoscope



Benefits of in-office biopsy



Cost-minimising

Multiple European studies also concluded that in-office biopsy is cost-minimising. The reported average cost per procedure for the in-office biopsy from three studies is **€899** versus **€3669** for the operating theatre biopsy.³⁻⁵

In the UK, the Scottish Health Technologies Group conducted a Budget Impact Analysis and found that the average resource-saving with in-office biopsies per annum over 5 years was in excess of **£400,000**.²



Improves patient pathway and outcome

Safe & Efficient:

The in-office biopsy showed 71% and 97% sensitivity and specificity for identifying malignancy in patients with suspicious laryngeal and pharyngeal lesions. The in-office biopsy was generally found to be safe with low complication rates.²

Shortens Diagnostic time:

In-office biopsy reduced the time from consultation to biopsy to 8 days on average.⁷ Overall time until the start of the treatment was also significantly reduced (**In-office: 24.2 ± 13.9 days vs standard: 48.8 ± 49.4 days**). This was concluded from a retrospective review of 116 patients undergoing in-office biopsy of oropharynx, larynx, or hypopharynx were included.⁸

The in-office setting enables procedures without the use of GA²

Provider benefit

- Potential to shorten theatre patient waiting list and prioritises more complex ENT procedures.⁷
- Visualisation of designated lesion as awake patients can control laryngeal function.⁶
- Outpatient setting, avoids overnight hospital stay.⁷



CLINICAL EVIDENCE

Case examples of in-office biopsy using aScope 4 RhinoLaryngo⁹

Mr Vivek Kaushik, Consultant ENT & Thyroid Surgeon & Clinical Lead for ENT Stepping Hill Hospital, Stockport

CASE #1

VALLECULA TUMOUR, T3 N0 M0

CLINICAL PRESENTATION: Incidental epiglottic abnormality found during gastroscopy to investigate haematemesis. Anaesthetic assessment deemed the patient high-risk for GA. CT and MR imaging found a 16 mm solid enhancing mass in the right vallecula. Two biopsies were successfully taken at the primary site using Ambu aScope 4 RhinoLaryngo Intervention.

LOCATION: Inpatient on medical ward

BIOPSY DIAGNOSIS: squamous cell carcinoma (SCC) in-situ with foci suspicious of invasive SCC

TREATMENT OUTCOME: treatment with radical radiotherapy with curative intent

CASE #2

TONSIL REMNANT TUMOUR, T3 N2B M0, P16+

CLINICAL PRESENTATION: The patient presented progressive dysphagia, and a right-sided tumour was noted on fiberoptic laryngoscopy. Tumour was not visible on oral examination as the patient was Mallampati class 3. This also meant that the tumour was not amenable to trans-oral biopsy. Patient comorbidities included obstructive sleep apnoea, hypertension, gout and gastroesophageal reflux disease. At the time of the presentation, there was a shortage of hospital beds due to COVID-19. The patient was unfit for MR; however, CT imaging showed a large enhancing right tonsillar mass, severely constricting the oropharynx and measuring 48mm in a craniocaudal extent. Two biopsies were taken using aScope 4 RhinoLaryngo Intervention at the primary site on the same day.

LOCATION: Attended emergency department

BIOPSY DIAGNOSIS: Biopsy result showed a mild-moderate dysplasia. Subsequent core-needle biopsy taken from neck nodes (at Day 11) confirmed metastatic SCC, which was P16+

MDT OUTCOME: treatment with chemoradiotherapy with curative intent

CASE #3

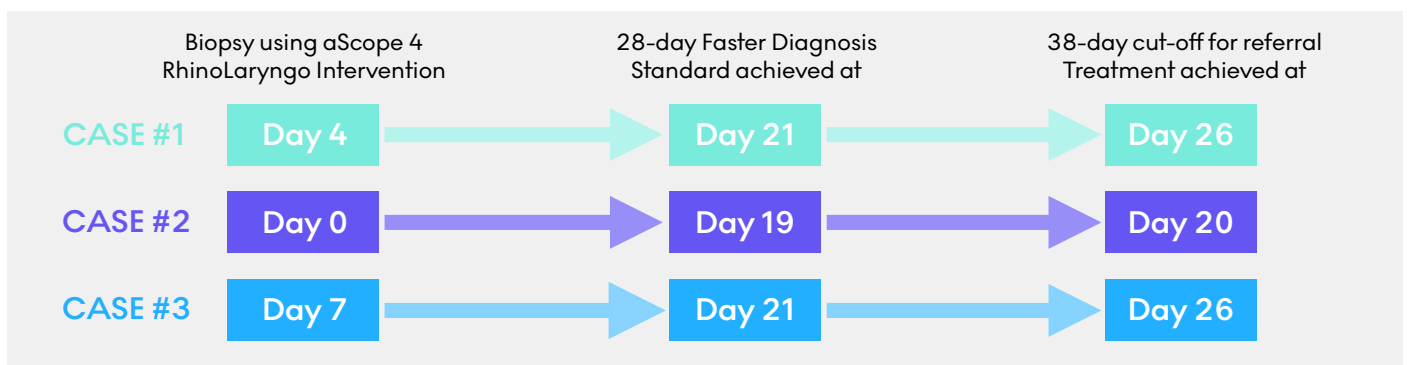
TONGUE BASE TUMOUR, T2 N2B M0, P16+

CLINICAL PRESENTATION: The patient was referred to the clinic with two months of progressive dysphagia and regurgitation episodes. The patient was aware of a left-sided neck lump, weight loss and subtle hot-potato speech that was audible during the consultation. The patient was fit and well and was scheduled for panendoscopy and biopsy under GA. Ultrasound-guided core-needle biopsy from the neck nodes was requested. CT and MR imaging showed a 25 x 34 mm mass in the left-posterior tongue base, constricting the oropharynx. Following discussion, this case was suitable for biopsy with aScope 4 RhinoLaryngo Slim. Biopsy of the primary site under GA and core-needle biopsy of neck nodes scheduled for day 15 and day 25 were not needed.

LOCATION: Attended outpatient

BIOPSY DIAGNOSIS: SCC, P16+

MDT OUTCOME: treatment with chemoradiotherapy with curative intent



CONCLUSION



In all three cases, the in-office biopsy using the aScope 4 RhinoLaryngo Intervention shortened the patient journey to their treatment. In all three cases, general anaesthetic, surgery and the need for a post-operative surgical bed were avoided. It helped achieve the 28-day faster diagnosis standard, ensuring compliance with the 38-day cut-off for referral to the treating trust. Consequently, patients were able to start cancer treatments earlier. These three cases show that aScope RhinoLaryngo Intervention and early biopsy in topical anaesthesia show promising performance and might have a place in diagnosis of ENT cancer. Further evidence must show the exact role/place.

First experiences with a new flexible single-use rhino-laryngoscope with working channel - a preliminary study

Becker et al., 2019¹⁰

AIM

To gain first experiences using the new aScope 4 Rhino Laryngo Intervention.

METHOD

10 consecutive patients were examined with the aScope 4 RhinoLaryngo Intervention by 6 different ENT doctors in 18 procedures.

Procedures included Rhino-laryngoscopy (n=15) and Rhino-laryngoscopy with biopsy (n=3; from the nasal cavity, the larynx and the hypopharynx, respectively).

Clinicians filled out a questionnaire concerning image quality, manoeuvrability, ergonomics of the handle and overall impression of the system on a 5-point scale (1-very poor to 5-very good).

Complications (epistaxis or pain) were evaluated.

KEY OUTCOMES

- The overall evaluation, ergonomics of handle, manoeuvrability and image quality were rated beyond “good” on average (Fig.1).
- Maneuverability without an instrument and with an instrument was rated 4.50 and 4.0, respectively (Fig. 2).
- One mild epistaxis case occurred, which was managed by conservative treatment.¹⁰
- Ambu aScope 4 RhinoLaryngo Intervention may be a good alternative to other conventional systems. Further studies with more patients and also focusing on the working channel have to follow.¹⁰

REFERENCES

1. Al-Jabir A, Kerwan A, Nicola M, Alsafi Z, Khan M, Sohrabi C, et al. Impact of the Coronavirus (COVID-19) pandemic on surgical practice - Part 1. *Int J Surg.* 2020; 79:168-79.
2. Scotland, H.I, 2018. What is the clinical and cost effectiveness of outpatient biopsy for diagnosis of suspicious lesions of the larynx, pharynx and tongue base?. In response to an enquiry from Queen Elizabeth University Hospital, NHS Greater Glasgow and Clyde, [online] Evidence Note(Number 84). Available at: <http://file:///C:/Users/smpe/Downloads/Evidence-Note-84-Outpatient-Biopsies.pdf> [Accessed 9 April 2021].
3. Wellenstein DJ, Honings J, Schutte HW, Herruer JM, van den Hoogen FJA, Marres HAM, et al. Cost analysis of office-based transnasal esophagoscopy. *Eur Arch Otorhinolaryngol.* 2019;276(5):1457-63.
4. Schimberg AS, Wellenstein DJ, van den Broek EM, Honings J, van den Hoogen FJA, Marres HAM, et al. Office-based vs. operating room-performed laryngopharyngeal surgery: a review of cost differences. *Eur Arch Otorhinolaryngol.* 2019; 276(11): 2963-73.
5. Wellenstein DJ, Schutte HW, Takes RP, Honings J, Marres HAM, Burns JA, et al. Office-Based Procedures for the Diagnosis and Treatment of Laryngeal Pathology. *J Voice.* 2018;32(4):502-13.
6. Wellenstein DJ, de Witt JK, Schutte HW, Honings J, van den Hoogen FJA, Marres HAM, et al. Safety of flexible endoscopic biopsy of the pharynx and larynx under topical anesthesia. *Eur Arch Otorhinolaryngol.* 2017;274(9):3471-6.
7. Cooper, F., Baig, H., Asimakopoulos, P., Kim W Ah-See, & Shakeel, M. Successful adaptation during COVID-19 pandemic: suspected head and neck cancer biopsies under local anaesthetic. *MedNEXT Journal of Medical and Health Sciences,* 2020;1(1), 15-18.
8. Lippert D, Hoffman MR, Dang P, McCulloch TM, Hartig GK, Dailey SH. In-office biopsy of upper airway lesions: safety, tolerance, and effect on time to treatment. *Laryngoscope.* 2015;125(4):919-23.
9. Utility of RhinoLaryngo Intervention scopes in the outpatient setting. Available at: <https://www.ambu.co.uk/education/educational-videos>. Accessed 25/02/21.
10. Becker S, Hagemann J, O'Brian C, Weber V, Döge J, Helling K, et al. First experiences with a new flexible single-use rhino-laryngoscope with working channel - a preliminary study. *Laryngorhinotologie.* 2019;98(S 02):11333.

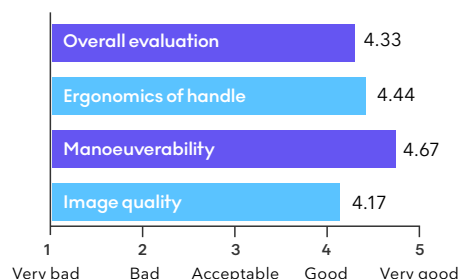


Fig 1. Evaluation of the characteristics of the aScope 4 RhinoLaryngo Intervention

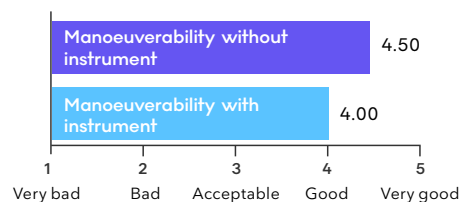
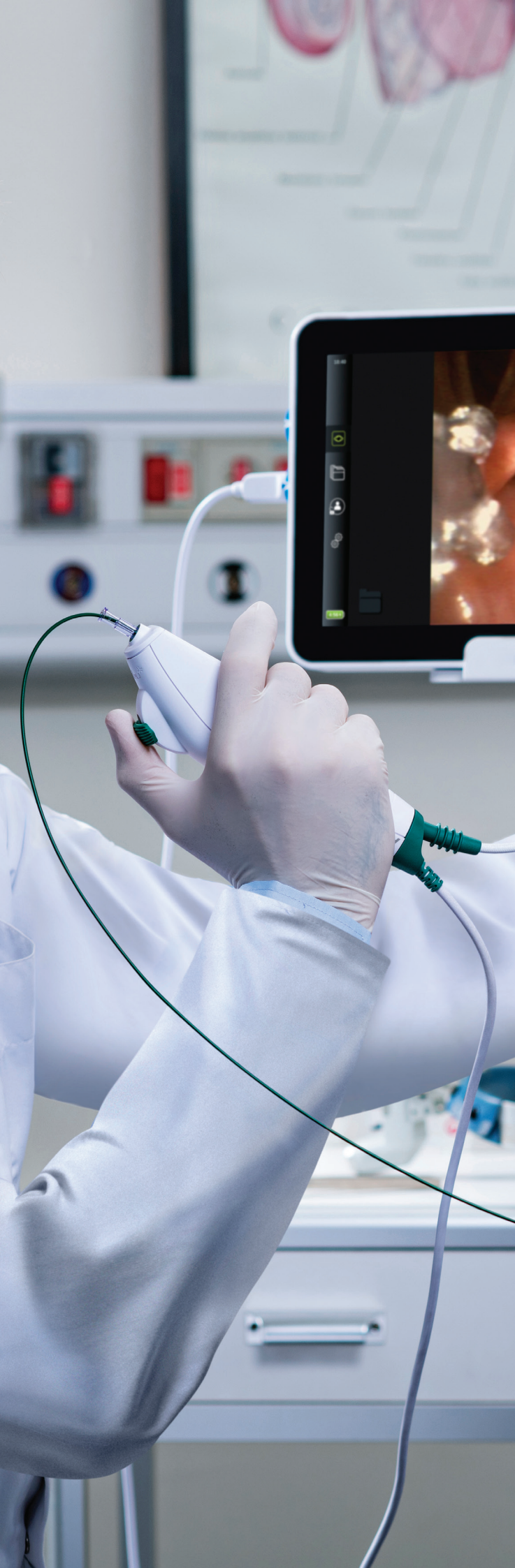

Fig 2. Evaluation of manoeuvrability of the aScope 4 RhinoLaryngo Intervention with and without the use of an instrument



Ambu

Ambu A/S
Baltorpbakken 13
2750 Ballerup
Denmark
+45 72 25 20 00
ambu.com
www.ambu.com/ent